

Case Report

Pitfalls in Laparoscopic Inguinal Hernia Surgery – Occult Trocar Injury of the Ilioinguinal Nerve Causing Severe Chronic Pain

René Gordon Holzheimer*

Day Surgery Clinic, Ludwig Maximilian University of Munich, Germany

*Corresponding author

René Gordon Holzheimer, Day Surgery Clinic, Ludwig-Maximilians University, Tegernseer Landstrasse 8, D-82054 Sauerlach, Germany, Tel: 49-8104-668-454; Fax: 49-8104-668-453; Email: rgholzheimer@t-online.de

Submitted: 18 February 2017

Accepted: 05 March 2017

Published: 16 March 2017

ISSN: 2379-0911

Copyright

© 2017 Holzheimer

OPEN ACCESS

Keywords

- Trocar injury
- Inguinal hernia repair
- Chronic pain
- Nerve entrapment

Abstract

Chronic postoperative groin pain is considered as complication of inguinal hernia repair. However, in most studies the analysis of the development of chronic pain is often weak or inconsistent. Occult groin pain may have serious impact on the quality of life of patients. Inguinodynia, a synonym for chronic groin pain, may have several, possibly overlapping, causes, e.g., pre- and postoperative nerve entrapment, mesh associated tissue reaction, injury by tacks or staples, delayed infection, which may cause difficulty in reaching a diagnosis. Some authors believe the incidence of chronic postoperative groin pain – 2%-12% in studies – is therefore underreported. Laparoscopic inguinal hernia repair seem to have less postoperative pain than open inguinal hernia repair which led to the conclusion it may be useful in pain prophylaxis. Trocar injury to intra-abdominal or abdominal wall vessels may occur, although there are only a few reports on trocar injury available. The direct injury to the ilioinguinal nerve by trocar insertion has not been published as case report. However, the risk of direct trocar injury to the cutaneous nerves of the lumbar plexus is evident, especially with regard to the variations in anatomic distribution. In this case report the history of a patient who suffered from severe chronic pain in relation to direct ilioinguinal nerve injury in the left groin after TAPP inguinal hernia treatment of a median suprapubic and right inguinal hernia for 10 years. The evidence for direct trocar injury of the ilioinguinal nerve is presented. Unfortunately this patient may suffer from a resistant complex regional pain syndrome (CRPS). Awareness of the risk of trocar injury may help to avoid this complication.

ABBREVIATIONS

TAPP: Transabdominal Preperitoneal Hernia Repair; TEP: Total Extraperitoneal Hernia Repair; IIN: Ilioinguinal Nerve; IHN: Iliohypogastric Nerve; GNF: Genitofemoral Nerve; CRPS: Complex Regional Pain Syndrome

INTRODUCTION

Chronic postoperative pain in the groin after open or laparoscopic inguinal hernia repair is considered as postoperative complication of inguinal hernia repair [1].

Despite this recognition it is rather difficult to obtain information on the pathogenesis of chronic pain in many studies. Most reports focus on recurrence, intraoperative complications, hematoma, seroma, infection, mesh related complications or mesh fixation complications [2]. Injury to genitofemoral, ilioinguinal and iliohypogastric nerve has been associated with open groin hernia repair, injury to the lateral cutaneous femoral nerve to laparoscopic hernia repair. However, it is obvious that many studies of laparoscopic inguinal hernia repair in the last years

do not report any intra- or postoperative complications. Chronic pain has been observed rarely after laparoscopic operation in recent publications [3]. The analysis of chronic pain, if reported, is often vague or inconsistent. Chronic groin pain may be caused by dissection and injury to nerves, mesh tissue reaction and/or mesh fixation by tacks/staples or by ignoring preoperative nerve entrapment. Vessel injury, e.g., lower epigastric artery, caused by trocar placement is mentioned rarely [4]. Direct trocar injury of the ilioinguinal/iliohypogastric nerves has not yet been published as major complication of laparoscopic inguinal hernia repair and contributing factor to complex regional pain syndrome.

CASE PRESENTATION

In October 2015 a patient and medical colleague presented himself for evaluation of severe chronic postoperative pain in the left lower abdomen and groin. The history of this patient is rather complex. A conventional cholecystectomy in 1987, a laparoscopic appendectomy in 1993 and a sclerotherapy for varicocele in the left groin in 2003 all were uneventful with regard to chronic postoperative pain. The index operation for the

chronic postoperative pain was a laparoscopic transabdominal preperitoneal (TAPP) repair of right inguinal hernia, a median suprapubic hernia and a trocar hernia of the right lower abdomen in 2006. For treatment of the median suprapubic hernia and the right inguinal hernia a 15x15 cm Medimex Mesh was implanted and fixed by tacks in the cranial part of the mesh only. The trocar hernia in the right lower abdomen above the inguinal hernia was closed by sutures. The adhesions in the right upper abdomen, caused by the open cholecystectomy, were eliminated. Postoperatively the patient suffered from recurrent chronic pain in the left groin, symphysis radiating into the genital region. The patient recognized that there were episodes of severe pain after sexual intercourse. Medical management of pain and infiltration of the median insertion of the inguinal ligament with dexamethasone/xylocaine failed to cure the pain. Several urological investigations were unable to find a cause of the severe pain. Magnetic resonance imaging of the lower spine showed disk herniation in the area of 3rd and 4th lumbar vertebra without sign of spinal stenosis, in the pelvis the mesh in the right groin overlapped the symphysis to the left groin. No other defect or pathology could be identified as cause of the pain. The resistant pain in the lower abdomen led to a diagnostic laparoscopy in June 2014. Adhesions to the mesh were cut, the mesh sealed off with "Hemopath" and "Tachosil". Unfortunately this did not help to eliminate the pain. The clinical diagnosis of a complex regional pain syndrome type II led to the sympathicolysis treatment with the injection of 2ml ethanol 95% in the segment L3 in May 2015. The patient did not observe any improvement.

In October 2015 the patient's left groin was extremely painful on pressure and percussion. He was unable to give an exact determination according to the Visual Analogue Scale (VAS), the pain intensity during the day changed, ranging from 5-7. The color-coded duplex sonographic examination showed no vascular alteration or pathological lymph node enlargement. On intra-abdominal pressure elevation a small prolapse in the area of the deep inguinal ring was demonstrated. Infiltration with xylocaine 2% in the left groin and lateral to the deep inguinal ring led to significant reduction of pain in the left groin. The result of the color-coded duplex sonography and the infiltration was discussed with the patient with regard to isolated nerve entrapment of the ilioinguinal nerve. The risk of continuous pain due to other confounding factors and the complex regional pain syndrome were mentioned. The patient decided after several days to have the revision of the groin and the tailored neurectomy. Preoperative laboratory investigation showed no abnormalities in inflammatory parameters, e.g. CRP, with the exception of slightly elevated cholesterol levels. The operation took place in October 2015 in modified general anesthesia without muscle relaxants and with regional nerve block. The posterior wall of the inguinal canal and the deep inguinal ring showed a deficiency as a complex direct hernia. The former trocar insertion - the scar in the skin - caused a severe damage to the ilioinguinal nerve, now embedded in massive scar tissue lateral to the deep inguinal ring. Medial to the scar tissue and the inner ring the normal nerve was identified. A tailored neurectomy of the injured part of the nerve together with scar tissue was performed and the material sent for histological evaluation. The trocar insertion site outside and the scar tissue with the nerve inside has been documented by photo

(Figure 1-3). The scar tissue excision revealed a small defect in the former trocar insertion area. The fascial defect was closed by suture technique (modified Shouldice technique) combined with tailored mesh implantation (modified Lichtenstein technique) with additional fixation of the mesh to the anterior wall of the inguinal canal. Histological evaluation of the muscle-nerve tissue showed dense collagen fibrotic scar tissue and degeneration of nerve tissue with signs of compression (Figure 4,5). The first 10 weeks after operation were uneventful. 12 weeks postoperatively sexual intercourse was followed by severe pain. The Urology Technical University Clinic Munich (TUM) could not demonstrate any other pathological cause for the patient's complaints. According to their judgment the patient suffered from complex regional pain syndrome (CRPS). The magnetic resonance imaging examination of the pelvis demonstrated no hematoma, seroma, recurrence, but a large dense mesh (TAPP 2006) scar tissue in the preperitoneal level 10 cm in the right groin overlapping the symphysis 5 cm to the left groin. 5 months after the tailored neurectomy and open repair the patient suffers again from severe pain, range 5-7 VAS.

DISCUSSION

Inguinodynia is the second most common complication occurring after inguinal hernia repair [5], reason enough to look for prophylaxis. However, inguinal neuralgia [6] and injury to nerves after inguinal hernia surgery [7] were not considered as an important common risk factor. Nerve injury has been reported to occur in 2% of laparoscopic hernia repair and to be

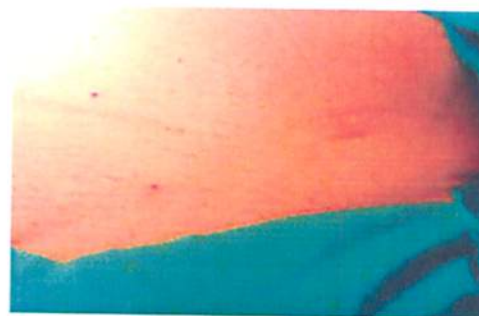

Figure 1 Left groin with scar caused by trocar insertion.

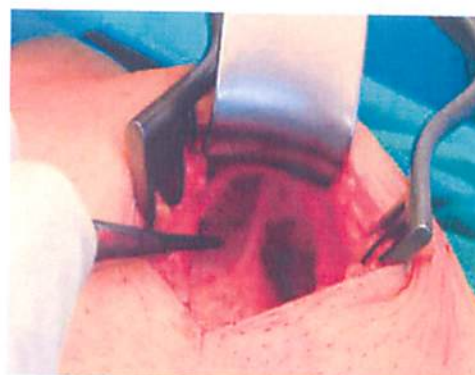

Figure 2 Inspection of the left lateral groin with scar tissue resulting from the trocar insertion above the external fascia.

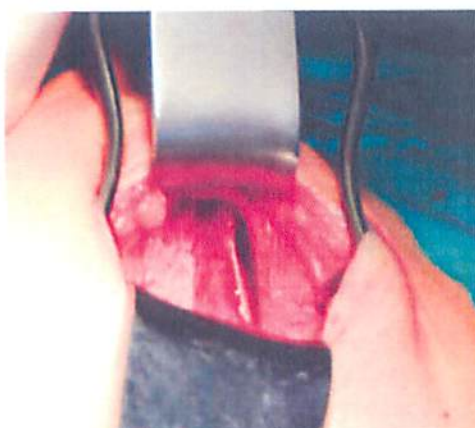

Figure 3 Below the external fascia there is fibrous scar tissue around the inguinal nerve.

entrapment neuralgia after open and laparoscopic hernia repair has been reported in up to 12% of patients [12] and may cause disabling pain [13]. Patients with neuralgia may suffer a longtime - more than 10 years - until a cause for the chronic pain in the groin can be established. Obviously there is no simple solution to the problem. It is questionable to recommend endoscopic technique as prophylactic measure [14-16].

Predictive independent risk factors for chronic inguinal pain are inguinal pain before surgery, bassini repair and perioperative lesion of the IIN [17]. Abdominal wall incision/dissection below the level of the anterior superior iliac spine may have the potential for iliohypogastric or ilioinguinal injury, both in open anterior hernia repair and trocar placement in laparoscopic TAPP/TEP hernia repair [18,19]. In open inguinal hernia repair the incidence of neuralgia was significantly lower in the IIN neurectomy group (3% versus 26%) [20]. The awareness of anatomical variations is instrumental to reduce the incidence of postoperative pain [21]. The course of the ilioinguinal and iliohypogastric nerve may vary in up to 59% [22], but this has not been agreed upon by all [23]. In contrast to the previously accepted opinion, the dissection and placement of staples either cranial to iliopubic tract or lateral to the anterior superior iliac spine, which has been performed in the patient, may result in injury of nerves [8]. The femoral nerve may be damaged by suture or staples, tissue scar entrapment, local anesthesia blockade or direct compression [7]. Reports on direct trocar injury of the ilioinguinal nerve are not available. Here we

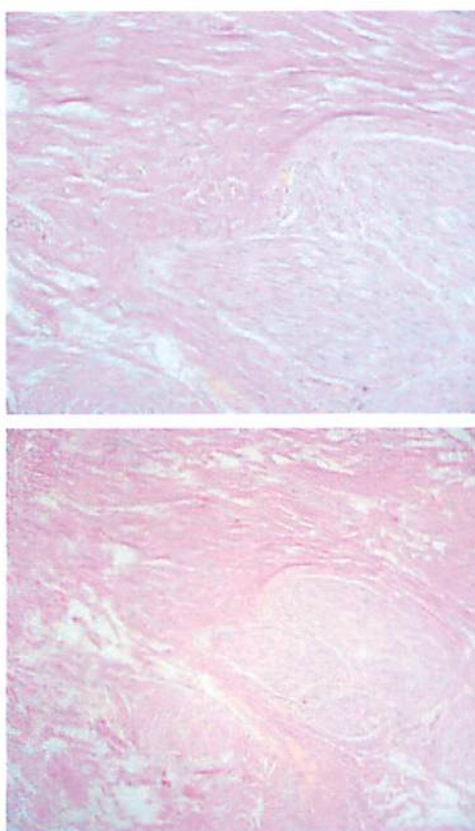


Figure 4 Hypocellular and densely fibrous scar tissue on the left and traversing nerves on the right hand side (van Gieson stain, x10 Objective). Thickened epineurium. Some nerve fibers with degenerative axonal swelling.

the most common complication of laparoscopic hernioplasty, particularly the TAPP technique [8]. Laparoscopic nerve injuries usually involve the femoral branch of the genitofemoral nerve and the lateral cutaneous femoral nerve of the thigh. It has been recognized that tacking devices penetrate tissues more deeply and may injure the ilioinguinal and iliohypogastric nerve as well [9,10]. Postoperative neuralgia may occur in 4-5% of patients after laparoscopic inguinal hernia repair, e.g. TAPP [11],

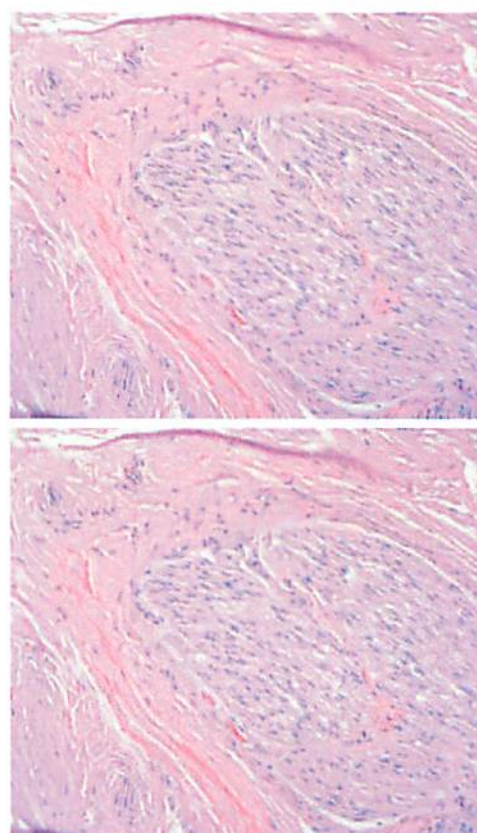


Figure 5 One nerve surrounded by scar tissue (H&E stain, x20 Objective). Fibrous thickening of the outer nerve capsule. Axonal swelling and fragmentation within some nerve fibers recognizable.

present evidence for direct trocar injury of the left ilioinguinal nerve leading to nerve destruction and chronic pain.

Diagnosis of nerve injury is based on patient history and physical exam [24]. Ilioinguinal nerve entrapment is associated with pain in the lower abdomen and inguinal region, sensory abnormalities and tenderness in palpation. This injury may be difficult to diagnose as genitofemoral nerve entrapment and non-neurological conditions of the lower abdomen may cause similar pain. Pain in the inguinal region, radiating into the genital region, as in this case, may be caused by ilioinguinal nerve entrapment [25]. Neuropathic groin pain may be due to a neuroma formation of the IIN, IHN or GFN. In case of postherniorrhaphy testicular pain symptoms the genitofemoral nerve injury may have to be considered as differential diagnosis. For a designed tailored therapeutic approach it is important to find out which nerve is injured [26]. Nerve blocks are therefore essential for diagnosis of the nerve entrapment [27,28]. Diagnosis of ilioinguinal nerve entrapment may be delayed for 12.8 months in non-surgical patients [29], in this patient for 10 years. The diagnosis of chronic postoperative groin pain is not an easy choice, however. The indication for operative treatment, e.g., tailored neurectomy, should wait to results of regional infiltration with xylocaine/lidocaine.

Neurectomy may be successful in 77% of genitofemoral neuralgia and 88% of ilioinguinal neuralgia [30], it may even influence sexual function without relevant complications [31]. Mesh removal along with stuck IIN and staple detachment from peritoneum were considered to be the gold standard for pain reduction [32]. Laparoscopic removal of staples/tackers in the inguinal region can be performed with variable success as the tackers/staples may be deeply embedded in the tissue and not seen during laparoscopy. Fluoroscopy may help to identify the staples [33]. Endoscopic technique for neurectomy of the genitofemoral or ilioinguinal nerve is recommended but large experience is not available [12]. Combined laparoscopic and open treatment for chronic groin pain is recommended in case where nerve blocks and conservative treatment do not work [28]. Alternatively, stimulator of IIN and GFN for sustained suppression of intractable neuropathic testicular pain may be implanted [34]. However, in case of chronic regional pain syndrome (CRPS) [35] non recovering patients should be evaluated for causal lesions, e.g., nerve entrapment, mesh inflammatory reaction and mesh fixation by tacks/staples, impingement, infections, tumors, or polyneuropathy and circulatory insufficiency. CRPS is no longer considered to represent a psychosomatic illness, but a complication of injury in biologically susceptible individuals [36].

ACKNOWLEDGEMENT

Professor Dr. Med. Walter Nathrath, Landshut/München, Germany has helped me with the histological evaluation of the scared nerve tissue taken out in the left groin.

REFERENCES

1. Bozok M, Schuster R, Stewart D, Hicks K, Greaney G, Waxman K. Disability and chronic pain after open mesh and laparoscopic inguinal hernia repair. *Am Surg.* 2003; 69: 839-841.
2. Shah NR, Mikami DJ, Cook C, Manilchuk A, Hodges C, Memark VR, et al. A comparison of outcomes between open and laparoscopic surgical repair of recurrent inguinal hernias. *Surg Endosc.* 2011; 25: 2330-2337.
3. Hallén M, Bergenfelz A, Westerdahl J. Laparoscopic extraperitoneal inguinal hernia repair versus open mesh repair: longterm follow up of a randomized controlled trial. *Surgery.* 2008; 143: 313-317.
4. Hurd WW, Pearl ML, DeLancey JO, Quint EH, Garnett B, Bude RO. Laparoscopic injury of abdominal wall blood vessels: a report of three cases. *Obstet Gynecol.* 1993; 82: 673-676.
5. Malekpour F, Mirhashemi SH, Hajinasrolah E, Salehi N, Khoshkar A, Kolahi AA. Ilioinguinal nerve excision in open mesh repair of inguinal hernia--results of a randomized clinical trial: simple solution for a difficult problem? *Am J Surg.* 2008; 195: 735-740.
6. Purves JK, Miller JD. Inguinal neuralgia: a review of 50 patients. *Can J Surg.* 1986; 29: 43-45.
7. García-Ureña MA, Vega V, Rubio G, Velasco MA. The femoral nerve in the repair of inguinal hernia: well worth remembering. *Hernia.* 2005; 9: 384-387.
8. Rosenberger RJ, Loeweneck H, Meyer G. The cutaneous nerves encountered during laparoscopic repair of inguinal hernia: new anatomical findings for the surgeon. *Surg Endosc.* 2000; 14: 731-735.
9. Dibenedetto LM, Lei Q, Gilroy AM, Hermey DC, Marks SC Jr, Page DW. Variations in the inferior pelvic pathway of the lateral femoral cutaneous nerve: implications for laparoscopic hernia repair. *Clin Anat.* 1996; 9: 232-236.
10. Lantis JC 2nd, Schwaitzberg SD. Tack entrapment of the ilioinguinal nerve during laparoscopic hernia repair. *J Laparoendosc Adv Surg Tech A.* 1999; 9: 285-289.
11. Kraus MA. Laparoscopic identification of preperitoneal nerve anatomy in the inguinal area. *Surg Endosc.* 1994; 8: 377-380.
12. Krähenbühl L, Striffeler H, Baer HU, Büchler MW. Retroperitoneal endoscopic neurectomy for nerve entrapment after hernia repair. *Br J Surg.* 1997; 84: 216-219.
13. Sampath P, Yeo CJ, Campbell JN. Nerve injury associated with laparoscopic inguinal herniorrhaphy. *Surgery.* 1995; 118: 829-833.
14. Berger D. Evidence-based hernia treatment in adults. *Dtsch Arztl Int.* 2016; 113:150-158.
15. Kouhia S, Vironen J, Hakala T, Paajanen H. Open Mesh Repair for Inguinal Hernia is Safer than Laparoscopic Repair or Open Non-mesh Repair: A Nationwide Registry Study of Complications. *World J Surg.* 2015; 39: 1878-1884.
16. Lundström KJ, Sandblom G, Smedberg S, Nordin P. Risk factors for complications in groin hernia surgery: a national register study. *Ann Surg.* 2012; 255: 784-788.
17. Liem MS, van Duyn EB, van der Graaf Y, van Vroonhoven TJ; Coala Trial Group. Recurrences after conventional anterior and laparoscopic inguinal hernia repair: a randomized comparison. *Ann Surg.* 2003; 237: 136-141.
18. Avsar FM, Sahin M, Arikan BU, Avsar AF, Demirci S, Elhan A. The possibility of nervus ilioinguinalis and nervus iliohypogastricus injury in lower abdominal incisions and effects on hernia formation. *J Surg Res.* 2002; 107: 179-185.
19. Whiteside JL, Barber MD, Walters MD, Falcone T. Anatomy of ilioinguinal and iliohypogastric nerves in relation to trocar placement and low transverse incisions. *Am J Obstet Gynecol.* 2003; 189: 1574-1578.
20. Dittrick GW, Ridl K, Kuhn JA, McCarty TM. Routine ilioinguinal nerve excision in inguinal hernia repairs. *Am J Surg.* 2004; 188: 736-740.

21. Bachul P, Tomaszewski KA, Kmiotek EK, Kratochwil M, Solecki R, Walocha JA. Anatomic variability of groin innervation. *Folia Morphol (Warsz)*. 2013; 72: 267-270.
22. al-dabbagh AK. Anatomical variations of the inguinal nerves and risks of injury in 110 hernia repairs. *Surg Radiol Anat*. 2002; 24: 102-107.
23. Lange JF, Wijsmuller AR, van Geldere D, Simons MP, Swart R, Oomen J, et al. Feasibility study of three-nerve-recognizing Lichtenstein procedure for inguinal hernia. *Br J Surg*. 2009; 96: 1210-1214.
24. Nahabedian MY, Dellon AL. Outcome of the operative management of nerve injuries in the ilioinguinal region. *J Am Coll Surg*. 1997; 184: 265-268.
25. ter Meulen BC, Peters EW, Wijsmuller A, Kropman RF, Mosch A, Tavy DL. Acute scrotal pain from idiopathic ilioinguinal neuropathy: diagnosis and treatment with EMG-guided nerve block. *Clin Neurol Neurosurg*. 2007; 109: 535-537.
26. Ducic I, Dellon AL. Testicular pain after inguinal hernia repair: an approach to resection of the genital branch of genitofemoral nerve. *J Am Coll Surg*. 2004; 198: 181-184.
27. Eichenberger U, Greher M, Kirchmair L, Curatolo M, Moriggl B. Ultrasound-guided blocks of the ilioinguinal and iliohypogastric nerve: accuracy of a selective new technique confirmed by anatomical dissection. *Br J Anaesth*. 2006; 97: 238-243.
28. Rosen MJ, Novitsky YW, Cobb WS, Kercher KW, Heniford BT. Combined open and laparoscopic approach to chronic pain following open inguinal hernia repair. *Hernia*. 2006; 10: 20-24.
29. Knockaert DC, D'Heygere FG, Bobbaers HJ. Ilioinguinal nerve entrapment: a little-known cause of iliac fossa pain. *Postgrad Med J*. 1989; 65: 632-635.
30. Starling JR, Harms BA, Schroeder ME, Eichman PL. Diagnosis and treatment of genitofemoral and ilioinguinal entrapment neuralgia. *Surgery*. 1987; 102: 581-586.
31. Zieren J, Rosenberg T, Menenakos Ch. Impact of ilio-inguinal nerve excision on sexual function in open inguinal hernia mesh repair: a prospective follow-up study. *Acta Chir Belg*. 2008; 108: 409-413.
32. Delikoukos S, Fafoulakis F, Christodoulidis G, Theodoropoulos T, Hatzitheofilou C. Re-operation due to severe late-onset persisting groin pain following anterior inguinal hernia repair with mesh. *Hernia*. 2008; 12: 593-595.
33. Wong J, Anvari M. Treatment of inguinodynia after laparoscopic herniorrhaphy: a combined laparoscopic and fluoroscopic approach to the removal of helical tackers. *Surg Laparosc Endosc Percutan Tech*. 2001; 11: 148-151.
34. Rosendal F, Moir L, de Pennington N, Green AL, Aziz TZ. Successful treatment of testicular pain with peripheral nerve stimulation of the cutaneous branch of the ilioinguinal and genital branch of the genitofemoral nerves. *Neuromodulation*. 2013; 16: 121-124.
35. Thimineur MA, Saberski L. Complex regional pain syndrome type I (RSD) or peripheral mononeuropathy? A discussion of three cases. *Clin J Pain*. 1996; 12: 145-150.
36. Oaklander AL, Horowitz SH. The complex regional pain syndrome. *Handb Clin Neurol*. 2015; 131: 481-503.

Cite this article

Holzheimer RG (2017) Pitfalls in Laparoscopic Inguinal Hernia Surgery – Occult Trocar Injury of the Ilioinguinal Nerve Causing Severe Chronic Pain. *J Surg Transplant Sci* 5(1): 1046.